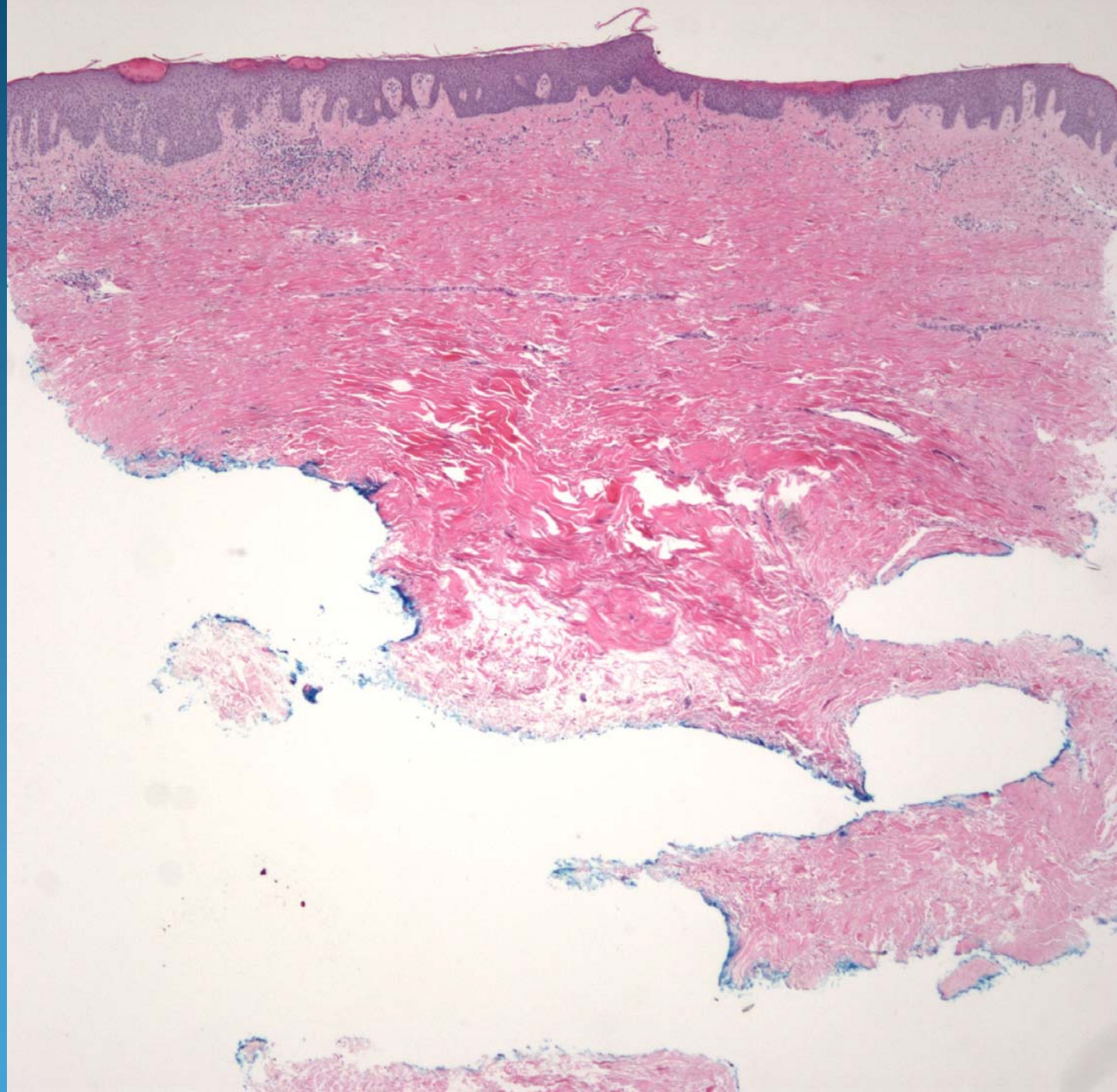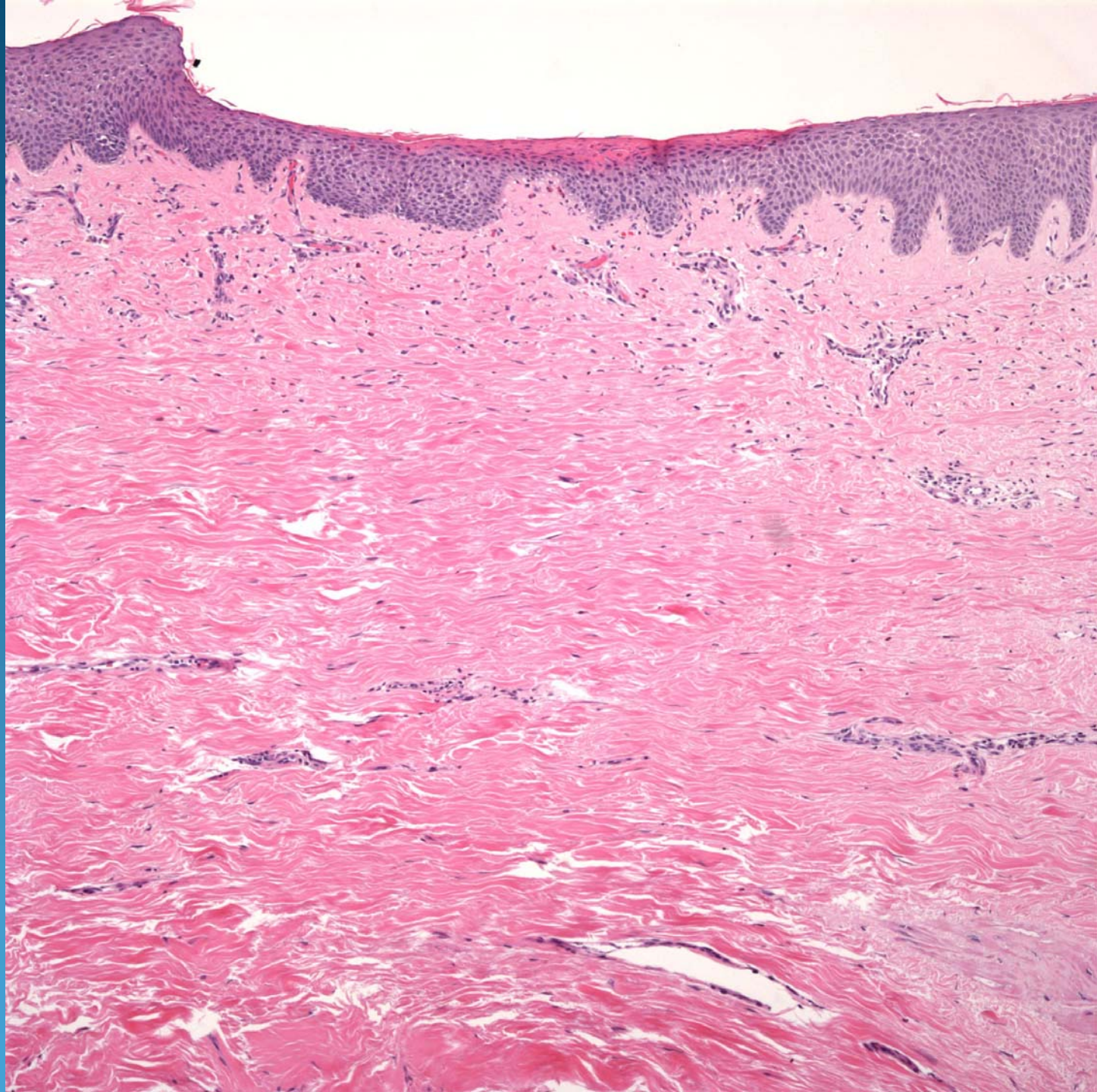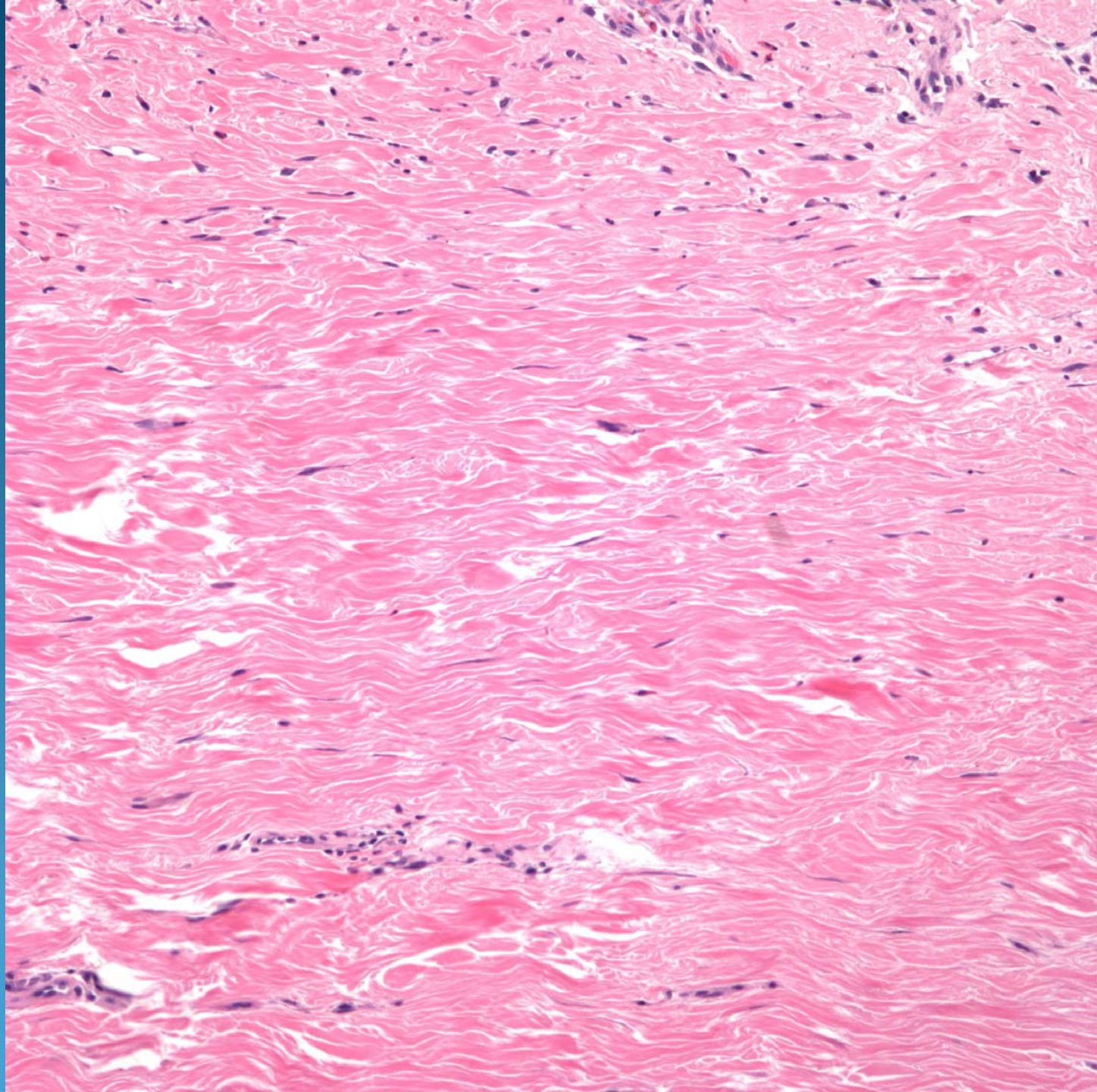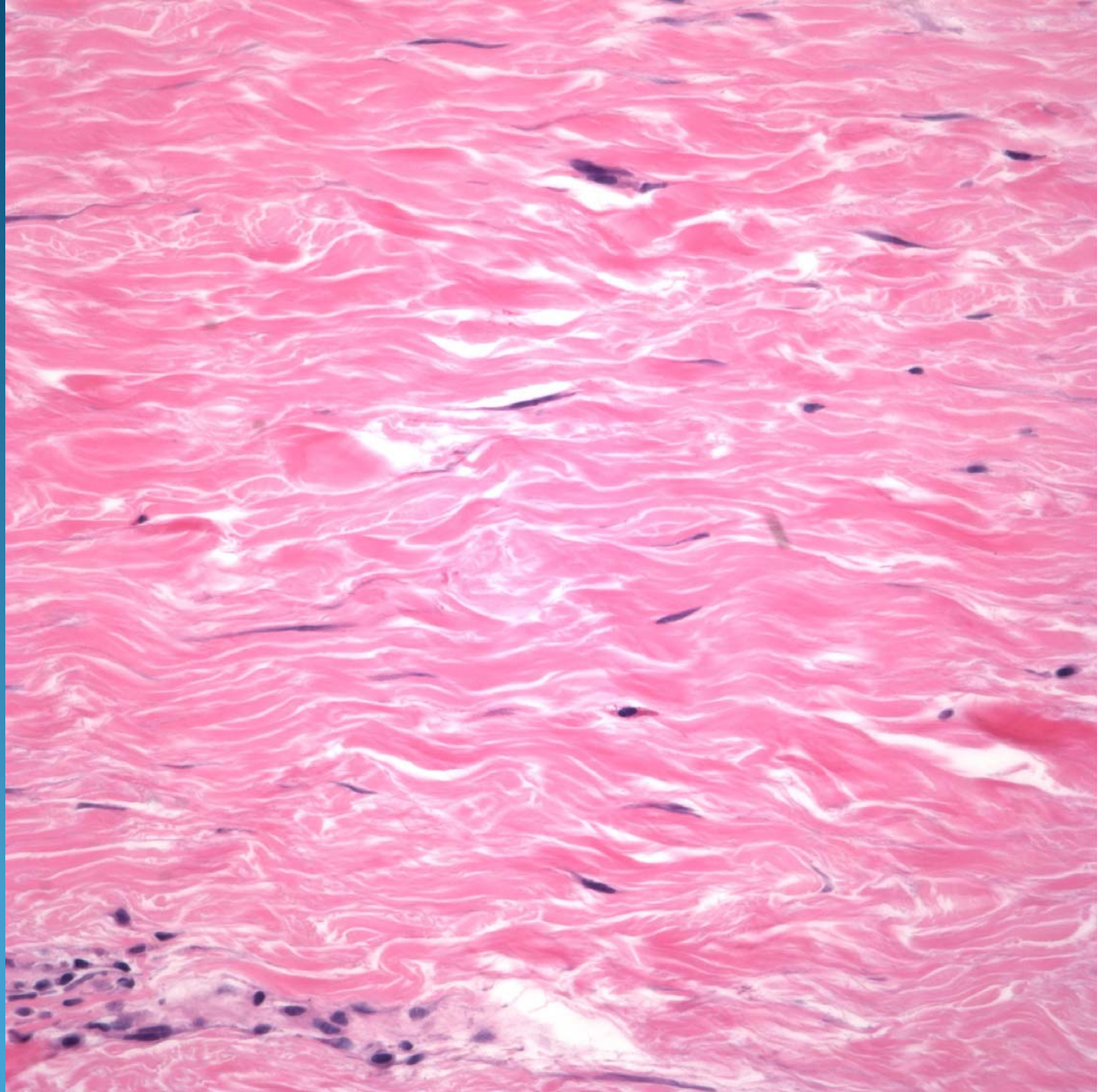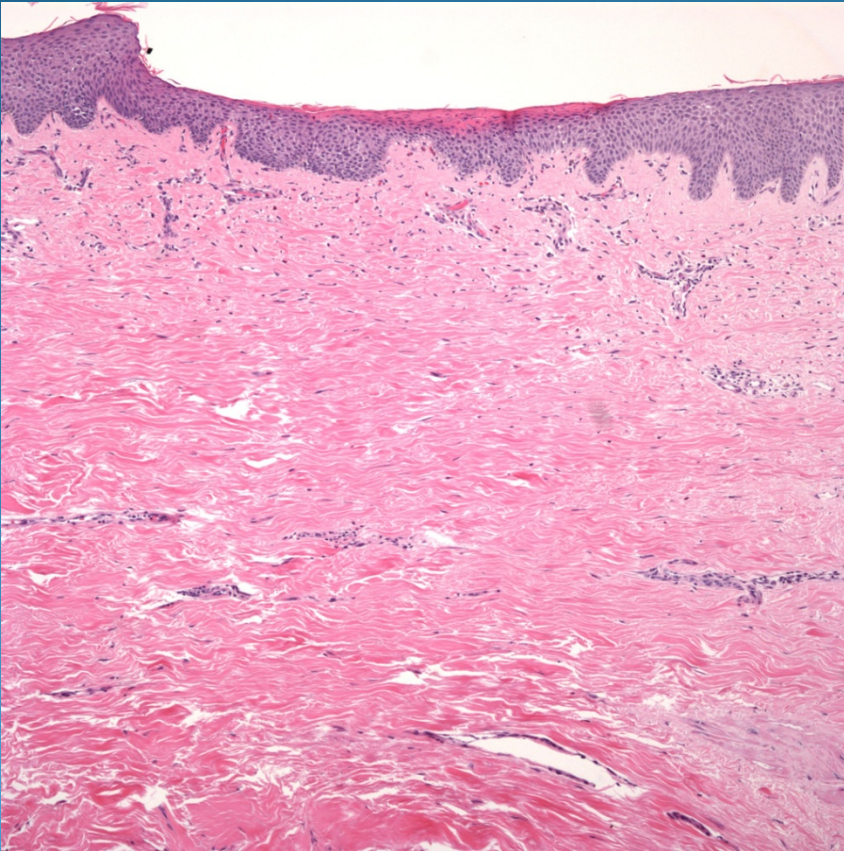


# Dermal Sclerosis consistent with Chronic Radiation Dermatitis

# Pearls



- Chronic lesions may show diffuse dermal sclerosis
- Variable changes of telangiectasia, edema, and vascular hyalinization
- May have atypia of fibroblasts with hyperchromasia
- DDX: Morphea, Chronic GVS, Acrodermatitis dermatitis atrophicans